The Journal of Sports Medicine and Physical Fitness
EDIZIONI MINERVA MEDICA

ARTICLE ONLINE FIRST
This provisional PDF corresponds to the article as it appeared upon acceptance.
A copyedited and fully formatted version will be made available soon.
The final version may contain major or minor changes.

Groin pain in athletes and non-interventional rehabilitative treatment: a systematic review.

Ileana RAMAZZINA, Benedetta BERNAZZOLI, Virginia BRAGHIERI, Cosimo COSTANTINO

The Journal of Sports Medicine and Physical Fitness 2018 Aug 28
DOI: 10.23736/S0022-4707.18.08879-5

Article type: Review Article

© 2018 EDIZIONI MINERVA MEDICA

Article first published online: August 28, 2018
Manuscript accepted: July 26, 2018
Manuscript revised: July 10, 2018
Manuscript received: April 18, 2018

Subscription: Information about subscribing to Minerva Medica journals is online at:
http://www.minervamedica.it/en/how-to-order-journals.php
Reprints and permissions: For information about reprints and permissions send an email to:
journals.dept@minervamedica.it - journals2.dept@minervamedica.it - journals6.dept@minervamedica.it

EDIZIONI MINERVA MEDICA

COPYRIGHT© EDIZIONI MINERVA MEDICA

Groin pain in athletes and non-interventional rehabilitative treatment: a systematic review.

Ileana Ramazzina[1], Benedetta Bernazzoli[2], Virginia Braghieri[3], Cosimo Costantino[1,2*].

[1] Department of Medicine and Surgery, University of Parma, Parma, Italy.

[2] Graduate School of Physical Medicine and Rehabilitation, Department of Medicine and Surgery, University of Parma, Parma, Italy.

[3] Physiotherapy Student, University of Parma, Parma, Italy.

*Cosimo Costantino, MD

Physical Medicine and Rehabilitation

Department of Medicine and Surgery

Address: Via Gramsci, 14, 43126, Parma, Italy

Phone number: +39 0521703517

Fax number: +39 0521702893

E-mail address: cosimo.costantino@unipr.it

This document is protected by international copyright laws. No additional reproduction is authorized. It is permitted for personal use to download and save only one file and print only one copy of this Article. It is not permitted to make additional copies (either sporadically or systematically, either printed or electronic) of the Article for any purpose. It is not permitted to distribute the electronic copy of the article through online internet and/or intranet file sharing systems, electronic mailing or any other means which may allow access to the Article. The use of all or any part of the Article for any Commercial Use is not permitted. The creation of derivative works from the Article is not permitted. The production of reprints for personal or commercial use is not permitted. It is not permitted to remove, cover, overlay, obscure, block, or change any copyright notices or terms of use which the Publisher may post on the Article. It is not permitted to frame or use framing techniques to enclose any trademark, logo, or other proprietary information of the Publisher.

COPYRIGHT© EDIZIONI MINERVA MEDICA

ABSTRACT

INTRODUCTION. Groin pain is a common complaint both in high-performance and recreational athletes. Diagnosis is based on the patient's history and physical examination. Imaging assessments are often considered to exclude other pathologies. To date there is no strong evidence to support conservative or surgical treatment options. The purpose of this study is to shed light on the more effective non-interventional rehabilitative treatments for the management of groin pain in athletes and, if possible, provide guidelines useful for clinical practice.

EVIDENCE ACQUISITION. The following electronic databases were searched: PubMed, Physiotherapy Evidence Database (PEDro), Scopus, Web of Science, Google and Google Scholar. Databases were investigated from January 1997 until March 2017.

EVIDENCE SYNTHESIS. The results reported in the randomized clinical trial studies highlight that active treatment is better than passive treatment to improve clinical signs of groin pain. Comparing the active strategy with multi-modal treatment the latter allows a faster return to sport activity. Although the evidence remains poor, all the included literature highlights that an integrated strategy which combines active and passive treatment, the assessment of perceived pain, a return to running programme and specific-sport exercises is an effective strategy for management of groin pain in athletes.

CONCLUSIONS

Although we shed some light on common key aspects able to improve the typical signs of groin pain, on the basis of available data we were unable to provide practice guidelines. Further studies are necessary to set the best treatment algorithm for the management of groin pain in athletes.

Key words: Athletes' injuries, Rehabilitative treatments, Inguinal pain, Multimodal approach.

This document is protected by international copyright laws. No additional reproduction is authorized. It is permitted for personal use to download and save only one file and print only one copy of this Article. It is not permitted to make additional copies (either sporadically or systematically, either printed or electronic) of the Article for any purpose. It is not permitted to distribute the electronic copy of the article through online internet and/or intranet file sharing systems, electronic mailing or any other means which may allow access to the Article. The use of all or any part of the Article for any Commercial Use is not permitted. The creation of derivative works from the Article is not permitted. The production of reprints for personal or commercial use is not permitted. It is not permitted to remove, cover, overlay, obscure, block, or change any copyright notices or terms of use which the Publisher may post on the Article. It is not permitted to frame or use framing techniques to enclose any trademark, logo, or other proprietary information of the Publisher.

COPYRIGHT© EDIZIONI MINERVA MEDICA

INTRODUCTION

Groin pain is a pathological condition described by many Authors[1-6] and it is reported in very physically active persons, well-described in high-performance athletes and sometimes in amateurs[7, 8].

This discomfort is localized in the anterior pelvic region and involves the inguinal region, which is a complex anatomical area located on the lower part of the abdominal wall. The anterior wall of the inguinal region is composed of the internal oblique muscle and the aponeurosis of the external oblique muscle. The posterior wall includes the fascia transversalis and the conjoint tendon on the common insertion of the internal oblique and transverse abdominus (TA) muscles[9, 10]. The complexity of this anatomical structure contributes to the complexity of groin pain diagnosis and treatment, and also to heterogeneous taxonomy.

Groin pain, sports hernia, adductor-related groin pain, Gilmore's groin, athletic pubalgia, footballer's groin injury complex, osteitis pubis, athletic pubalgia syndrome are different terms used to identify this pathological condition[11-14]. Taylor and colleagues introduced the term athletic pubalgia which refers to athletes' chronic inguinal or pubic-area pain that is only exertional and not explainable by a palpable hernia or other diagnosis[15]. Hegedus and colleagues define athletic pubalgia as groin pain present in athletes and referred to damage of tendons, fascia, sheaths or bone[16].

Groin pain in athletes is more common in men than in women[17, 18], probably for differences in pelvic anatomy, lower extremity alignment, and muscle activation[19-22]. Repetitive hyperextension of the trunk with hyperabduction of the thigh pivoting on the anterior pelvis and pubic symphysis (i.e. kicking, twisting and fast direction changes) are associated with groin pain onset. This mechanism occurs in sports like football, rugby, basketball, hockey, handball, swimming and running[14, 23-25].

There are intrinsic and extrinsic risk factors to the development of groin pain. The intrinsic risk factors are muscle weakness, inadequate muscle conditioning, poor groin flexibility, poor pelvic and core stability, ethnicity/race, increasing age. The extrinsic risk factors are associated with inadequate rehabilitation post-injury, inadequate warm up, fatigue, decreased fitness, muscle tightness, poor posture, neural tightness and recurrent injury[26]. Other predisposing factors are functional imbalance between abdominal and adductor muscles, significant difference in leg length, decreased hip movements (also due to femoroacetabular impingement)[27], reduced flexibility of the posterior muscle chain and/or of the iliopsoas, lumbar hyperlordosis, foot alterations, inadequate footwear and uneven playing fields[28-31].

Groin pain diagnosis is very difficult and complex because different pathologies, often coexisting, can cause anterior pelvic region pain[3, 7, 8, 32-38] (Figure 1). The diagnosis can be made if at least three out of the five clinical signs reported in Table I are present[9, 39]. In the Doha Agreement Meeting three

This document is protected by international copyright laws. No additional reproduction is authorized. It is permitted for personal use to download and save only one file and print only one copy of this Article. It is not permitted to make additional copies (either sporadically or systematically, either printed or electronic) of the Article for any purpose. It is not permitted to distribute the electronic copy of the article through online internet and/or intranet file sharing systems, electronic mailing or any other means which may allow access to the Article. The use of all or any part of the Article for any Commercial Use is not permitted. The creation of derivative works from the Article is not permitted. The production of reprints for personal or commercial use is not permitted. It is not permitted to remove, cover, overlay, obscure, block, or change any copyright notices or terms of use which the Publisher may post on the Article. It is not permitted to frame or use framing techniques to enclose any trademark, logo, or other proprietary information of the Publisher.

COPYRIGHT© EDIZIONI MINERVA MEDICA

major categories were defined to classify groin pain in athletes and carry out a correct diagnosis[40]: inguinal-related, pubic-related, iliopsoas-related, adductor-related groin pain; hip-related groin pain; other causes.

Athlete's pain history, clinical and imaging assessments are needed for a correct groin pain diagnosis. The clinical examination includes pelvic and hip regions palpation, hip and lumbar active and passive tests to measure Range of Motion (ROM), strength tests, pain provocation tests and neurological assessment[41, 42]. Mens and colleagues reported that the Active Straight Leg Raise (ASLR) test must be performed with and without a pelvic belt. The latter may be helpful in categorizing patients with pain in the groin area[43]. The imaging assessment is important to rule out other pathologies. Magnetic Resonance Imaging (MRI) is used to identify different lesions in athletes with clinical conditions referred to groin pain[44]. Other instrumental diagnosis techniques are ultrasound (US) and radiography[41]. Dynamic US can be used in asymptomatic élite athletes to assess a posterior wall defect and to monitor them during the sports season[14]. Moreover, surface electromyography (sEMG) can be used to measure specific muscle activation and to select appropriate exercises for prevention and treatment of groin injuries[45]. Isokinetic dynamometers can also be employed to investigate the hip muscle imbalance in athletes with osteitis pubis[46].

Groin pain in athletes is firstly treated with nonsurgical modalities, including heat or ice, anti-inflammatory medications, deep massage, stretching and rest followed by a gradual return to sport activities. In the last few years importance has been given to core stability and resolution of hip muscles imbalance. Surgical repair should be considered when conservative treatments fail[9, 31, 47]. The aim of a surgical approach is the tensioning or de-tensioning of the soft tissues of the inguinal region using open repair with or without mesh reinforcement, laparoscopic repairs and mini open repairs[19, 42, 48].

Groin injuries among athletes are correlated to different factors such as sport, age and level of competition. The discomfort and/or pain perceived by athletes can determine a prolonged absence from training and competitions, resulting in worsening of performance[49, 50]. Appropriate management of groin pain among athletes remains a significant challenge for both clinical practice and research. Surgical intervention for groin pain accounts for 75%, whereas conservative treatment is 25%. Occurrence of complications has been reported with respect to surgical intervention and injection therapy. To date there is no strong evidence to support any treatment option[40, 51].

The purpose of this study is to shed light on the more effective non-interventional rehabilitative treatments for the management of groin pain in athletes and, if possible, to provide guidelines useful for clinical practice.

This document is protected by international copyright laws. No additional reproduction is authorized. It is permitted for personal use to download and save only one file and print only one copy of this Article. It is not permitted to make additional copies (either sporadically or systematically, either printed or electronic) of the Article for any purpose. It is not permitted to distribute the electronic copy of the article through online internet and/or intranet file sharing systems, electronic mailing or any other means which may allow access to the Article. The use of all or any part of the Article for any Commercial Use is not permitted. The creation of derivative works from the Article is not permitted. The production of reprints for personal or commercial use is not permitted. It is not permitted to remove, cover, overlay, obscure, block, or change any copyright notices or terms of use which the Publisher may post on the Article. It is not permitted to frame or use framing techniques to enclose any trademark, logo, or other proprietary information of the Publisher.

COPYRIGHT© EDIZIONI MINERVA MEDICA

EVIDENCE ACQUISITION

The review was conducted and reported in accordance with the PRISMA statement.

Databases and search strategy

The following electronic databases were searched: PubMed, Physiotherapy Evidence Database (PEDro), Scopus and Web of Science.

The list of terms used for database strategy search is shown in Appendix A. Despite the Doha meeting suggestion[40], we included the most frequently used terms within the literature.

A manual search of reference lists of selected papers and reviews on the topics was carried out to identify additional relevant articles. To identify grey literature, a search was conducted in Google and Google Scholar using the same terms as Appendix A. The electronic databases were investigated from January 1997 until March 2017.

Selection criteria for treatment strategies

In order to find the most current non-interventional rehabilitative strategies for groin pain in athletes we included articles that met the following inclusion criteria based on PICO (Patient, Intervention, Comparison, Outcome) principles: treatment strategies including manual therapy, stretching and postural gym, neuromuscular coordination; athletes of both sexes; case-report/case-series studies and Randomized Clinical Trials (RCT); all types of individual or team sports; articles written in English. Exclusion criteria were surgical treatment, infiltration therapy, physical and instrumental therapy, pharmacological therapy, use of orthoses and mesotherapy.

Three authors (IR, BB and VB) independently screened the articles by title and abstract against the selection criteria. Articles that were unclear from their title or abstract were reviewed against the selection criteria through the full text. Any discrepancies between authors were resolved through discussion with the fourth author (CC). The second step was to screen all full-text articles that passed the first step. Conference and symposium abstracts were assessed but deemed unsuitable due to the limited body of data related to the study design and the intervention programme.

Data extraction and analysis

Data were extracted from the studies that met the inclusion criteria. In agreement with PICO principles, the data included the following: number of participants, type of sport, protocol of intervention, duration and frequency of intervention, outcomes, participant retention and dropouts, and adverse effects associated with intervention strategies.

This document is protected by international copyright laws. No additional reproduction is authorized. It is permitted for personal use to download and save only one file and print only one copy of this Article. It is not permitted to make additional copies (either sporadically or systematically, either printed or electronic) of the Article for any purpose. It is not permitted to distribute the electronic copy of the article through online internet and/or intranet file sharing systems, electronic mailing or any other means which may allow access to the Article. The use of all or any part of the Article for any Commercial Use is not permitted. The creation of derivative works from the Article is not permitted. The production of reprints for personal or commercial use is not permitted. It is not permitted to remove, cover, overlay, obscure, block, or change any copyright notices or terms of use which the Publisher may post on the Article. It is not permitted to frame or use framing techniques to enclose any trademark, logo, or other proprietary information of the Publisher.

COPYRIGHT© EDIZIONI MINERVA MEDICA

Assessment of risk bias

The level of evidence of the articles included were stratified, in accordance with the Oxford Centre for Evidence-Based Medicine (OCEBM)[52]. The methodological quality of RCT study included was also assessed using the PEDro scale check list (Table II).

EVIDENCE SYNTHESIS

Overview of the inclusion process and methodological quality assessment

The reviewing process is presented in Figure 2. Duplicate articles, review articles, unavailable full texts and articles out of topic were excluded from the initial records retrieved from different databases. From a total of 383 selected articles, 372 did not meet the inclusion criteria as previously reported in the Evidence Acquisition section. A total of 11 articles were included in this review. One of these[53] represents the follow-up study of a previous study[54]. Three articles are RCT[53-55], one article is a longitudinal single-cohort study[56], four articles are case-series[57-60] and the other three articles are case-reports[61-63].

The level of evidence according to the Oxford Centre for Evidence-Based Medicine (OCEBM)[52] is Level 4 for the case-reports[61-63], case-series[57-60] and the longitudinal single-cohort study[56]. For the other three articles included, the OCEBM level of evidence is between Level 1[53] and Level 2[54, 55].

For the three RCTs [53-55] the PEDro scale scores were also reported (Table II).

Details of the included articles

The details of the reviewed articles are reported in Table III. Most of the studies concern soccer and football players[53-60]. Other sports like rugby[53-56], hockey[53-55, 58], speed skating[55, 56, 59], basketball[54, 55], long distance running[53-56, 58, 59], tennis[54, 55, 58, 59], badminton[53, 54] and handball[53-55] are reported. In the RCTs the number of subjects is 68 in the study reported by Holmich and colleagues[54] and 54 in the study reported by Weir and colleagues[55]. In the case-series the number of subjects per study ranged from 4[60] to 44[58]. Studies also included subjects of different ages. Most studies included only male athletes[53, 54, 57, 60-63] while in the studies of Weir et al., 2009[59] and Weir at al., 2010[58] 3 and 7 female athletes were included respectively. In two studies there was only one female among all athletes included[55, 56].

All studies presented subjects with long-lasting groin pain. In most of the included studies athletes had already undergone many previous therapies without pain resolution[54, 55, 57, 59]. In the study of Weir and colleagues, 7 athletes out of 54 had not been subjected to any treatment[55]. In two case reports the athlete had been subjected to previous treatment such as US therapy[63] and conventional physical therapy[61].

This document is protected by international copyright laws. No additional reproduction is authorized. It is permitted for personal use to download and save only one file and print only one copy of this Article. It is not permitted to make additional copies (either sporadically or systematically, either printed or electronic) of the Article for any purpose. It is not permitted to distribute the electronic copy of the article through online internet and/or intranet file sharing systems, electronic mailing or any other means which may allow access to the Article. The use of all or any part of the Article for any Commercial Use is not permitted. The creation of derivative works from the Article is not permitted. The production of reprints for personal or commercial use is not permitted. It is not permitted to remove, cover, overlay, obscure, block, or change any copyright notices or terms of use which the Publisher may post on the Article. It is not permitted to frame or use framing techniques to enclose any trademark, logo, or other proprietary information of the Publisher.

COPYRIGHT© EDIZIONI MINERVA MEDICA

Self-reported questionnaires, physical performance scales and tests were used for athletes' clinical examinations[53-63]. In order to diagnose groin pain, four studies also utilized imaging assessments, i.e. pelvis radiography and bone scintigraphy[54], US imaging[56] and MRI[57, 60].

Outcomes of treatment strategies

The treatment strategies of the included studies are reported in Table VI. The common outcomes of all studies were the return to pre-injury activity levels and pain resolution after the specific treatment. In the RCT studies reported by Holmich and colleagues[53, 54] the effects of active treatment (AT) was compared with a physiotherapy treatment without active training (PT). The AT programme included mainly balance exercises and adductor and abdominal muscle strength exercises. No adductor muscle stretching exercises were allowed. The PT protocol included laser treatment, massage, transcutaneous electrical nerve stimulation and adductor, hamstring and hip flexor muscle stretching exercises. No athletic activity was permitted either for AT group athletes or for PT group athletes. At the end of the study 23 athletes belonging to the AT group returned to sport activity at their previous level whereas only 4 athletes belonging to the PT group returned to sport activity at their previous level. Data showed a significant difference in favour of AT strategy. Moreover, the follow-up study highlighted the long-lasting effect of the AT programme[53].

In the study reported by Weir and colleagues, the effects of Exercise Therapy (ET) strategy was compared with the Multi-Modal Treatment (MMT) programme[55]. The ET treatment included the exercises reported for AT in the study of Holmich and colleagues[54]. Moreover, athletes followed a return to running programme. The MMT programme included the Van Den Akker manual therapy method, adductor muscle stretching exercises and the same return to running programme reported for ET strategy. Athletes were able to return-to-activity after an average of 12.8 ± 6.0 and 17.3 ± 4.4 weeks, for the MMT and ET groups respectively. However, for the percentage of athletes who returned to sport activity, pain perceived during palpation and VAS score was not different between the two groups (50-55%). The effects of MMT strategy were also previously assessed in a retrospective case series study conducted by the same Authors[59]. Twenty-five out of the thirty athletes enrolled were treated once whereas five had undergone a second treatment. Results highlighted a significant statistical decrease of pain score during both activities of daily living (ADL) and sport activity. Moreover, 15 athletes returned to sport activity at pre-injury level, 12 returned under pre-injury level and 3 did not return to sports. In their two studies the Authors have ascribed the difference in athletes who were successfully treated to study design, and to the age and level of sport activity[55].

Jansen and colleagues[56] investigated the effects of a programme which included TA recruitment exercises, passive mobilization/manipulation of adductor muscles strength exercises and sport-specific exercises. At the end of 14 weeks' intervention 16 athletes reported improvement in sports

This document is protected by international copyright laws. No additional reproduction is authorized. It is permitted for personal use to download and save only one file and print only one copy of this Article. It is not permitted to make additional copies (either sporadically or systematically, either printed or electronic) of the Article for any purpose. It is not permitted to distribute the electronic copy of the article through online internet and/or intranet file sharing systems, electronic mailing or any other means which may allow access to the Article. The use of all or any part of the Article for any Commercial Use is not permitted. The creation of derivative works from the Article is not permitted. The production of reprints for personal or commercial use is not permitted. It is not permitted to remove, cover, overlay, obscure, block, or change any copyright notices or terms of use which the Publisher may post on the Article. It is not permitted to frame or use framing techniques to enclose any trademark, logo, or other proprietary information of the Publisher.

COPYRIGHT© EDIZIONI MINERVA MEDICA

restriction, 3 reported an increase in sports restriction and 2 maintained the same level. Data showed no significant association between abdominal muscle thickness and change in athletes' sports restriction.

In the study reported by Verrall and colleagues[57] athletes were followed for two football seasons. The treatment strategy was organized in three phases. For the first 12 weeks the athletes rested from all weight-bearing activities; only swimming, cycling and light upper body weights were allowed. The stepping activity was introduced from the 6th week whereas the return to run activity occurred from the 3rd month. Following the treatment programme 89% of athletes returned to competition in the first football season and all athletes by the second. In terms of symptoms resolution only 41% of athletes were without symptoms at the beginning of the first football season (20-24 weeks after diagnosis) whereas 81% of athletes were without symptoms by the end of the second season (24 months after diagnosis). However, the Authors highlight that 26% of athletes were playing at a lower competition level in the second season.

Weir and colleagues[58] demonstrated the beneficial effects of a treatment that enclosed both active and passive physical therapy. Specifically, the treatment consisted in specific motor control training for TA muscle function, manual therapy for hip joint and sacroiliac joints, agility drills and sport-specific exercises. Results showed that after treatment 38 out of 44 athletes returned to their same sport level (34 without any symptoms); the median time was 142 days. At mid-term follow-up (median 22 months) 23 out of 44 athletes were active at their previous level of sports and 5 were active at a higher level. However, 10/38 athletes had experienced a groin pain recurrence.

In the case series reported by Wollin & Lovell[60] the rehabilitation programme was organized in four different phases. In the first, pelvic floor and TA retraining using real time US and isometric hip adduction were performed. In the other three phases the treatment was based on core stability, gluteal and adductor muscle conditioning and two running programmes. At the end of the rehabilitation protocol all players returned to sport activity between 10 and 16 weeks. Moreover, no athletes reported recurrence of groin pain at 12 months follow-up.

Different integrated treatment strategies were reported in the three case-reports included: pelvic floor fascial mobilization associated with hip stabilizing exercises[61]; hip mobilization, sacroiliac joint manipulation, TA recruitment, core stability exercises, stretching, and on-field training exercises, agility exercises and swimming[62]; manual therapy, hip mobilization exercises, gluteal and trunk stabilization exercises, strength and aerobic training and sports-specific drills integrated with athlete's ongoing functional assessment[63]. At the end of the treatment strategy athletes had become pain-free and returned to their sport activity. Moreover, the follow-up study highlighted the long-lasting effect of treatments.

This document is protected by international copyright laws. No additional reproduction is authorized. It is permitted for personal use to download and save only one file and print only one copy of this Article. It is not permitted to make additional copies (either sporadically or systematically, either printed or electronic) of the Article for any purpose. It is not permitted to distribute the electronic copy of the article through online internet and/or intranet file sharing systems, electronic mailing or any other means which may allow access to the Article. The use of all or any part of the Article for any Commercial Use is not permitted. The creation of derivative works from the Article is not permitted. The production of reprints for personal or commercial use is not permitted. It is not permitted to remove, cover, overlay, obscure, block, or change any copyright notices or terms of use which the Publisher may post on the Article. It is not permitted to frame or use framing techniques to enclose any trademark, logo, or other proprietary information of the Publisher.

COPYRIGHT© EDIZIONI MINERVA MEDICA

Summary of the results

Our purpose was to investigate the effectiveness of different non-interventional rehabilitative treatment for the management of groin pain in athletes and provide guidelines for clinical practice.

In relation to the RCTs selected, Holmich and colleagues highlighted that the AT strategy was better than passive treatment and has a long-lasting beneficial effect[53]. Weir and colleagues[55] compared the ET and MMT protocols. Athletes enrolled in the MMT group returned to sport activity quicker than the ET group, but no significant differences were reported between groups either in terms of pain resolution or the percentage of athletes that returned to sport. In agreement with a previous review, multimodal strategy which includes manual therapy technique allows a faster return to sport activity compared to active exercise strategy[51]. It is noteworthy that only two RCTs provided insufficient evidence to define the best treatment strategy for groin pain in athletes. However, it seems that AT and MMT could be appropriate strategies to determine a good return to sport activity. Very interestingly, although the evidence remains poor, the case-series and the case-reports included also point out that an integrated approach combining active and passive modalities could be an effective strategy for the management of groin pain in athletes. The main focus of active exercises is on improving muscle strength, TA recruitment, balance and coordination in order to determine an amelioration of postural stability of the pelvis. A starting period of activity without load on the pubic bone could produce good results[57]. Also, manual therapy can be performed to reduce pubic bone load[55, 59]. Moreover, increases in hip ROM and improved muscular stiffness are keys aims of treatment[54, 55, 58]. Of note, the intervention programmes reported include different exercises and manipulation techniques, so it is difficult to assess the individual contribution to groin pain management.

In this review it also emerged that the treatment protocol should include the return to running programme and sport-specific exercises. Moreover, it is very important to instruct the athlete on his own pain perception and to increase the workload only when he is pain free. The role of the physiotherapist, who supervises and instructs athletes to achieve best performance, is very important[58]. It is noteworthy that none of the selected studies reported adverse effects associated with the treatment strategy proposed. Moreover, no injury recurrence events, or only a very low rate, were highlighted[58].

Limitation of the study and further research

The limitation of this review is related to the few high quality studies available concerning the non-interventional rehabilitative management of groin pain in athletes. Of 11 articles, only 2 were of high quality (PEDro scale score and OCEML level)[54, 55]. The selected studies are highly heterogeneous in terms of intervention strategy, frequency, duration and in terms of age, gender, sport level and sport

This document is protected by international copyright laws. No additional reproduction is authorized. It is permitted for personal use to download and save only one file and print only one copy of this Article. It is not permitted to make additional copies (either sporadically or systematically, either printed or electronic) of the Article for any purpose. It is not permitted to distribute the electronic copy of the article through online internet and/or intranet file sharing systems, electronic mailing or any other means which may allow access to the Article. The use of all or any part of the Article for any Commercial Use is not permitted. The creation of derivative works from the Article is not permitted. The production of reprints for personal or commercial use is not permitted. It is not permitted to remove, cover, overlay, obscure, block, or change any copyright notices or terms of use which the Publisher may post on the Article. It is not permitted to frame or use framing techniques to enclose any trademark, logo, or other proprietary information of the Publisher.

COPYRIGHT© EDIZIONI MINERVA MEDICA

activity. Accordingly, statistical pooling of the data was not possible.

CONCLUSIONS

Groin pain is a very complex physical condition that affects athletes and can keep them away from sport for a long period, determining loss of fitness and performances. Of note, no significant prevention programme for groin pain has been demonstrated[64]. The crucial aims of groin pain management are the reduction of pain and a fast return to pre-injury performances.

Although the evidence base is poor, we can shed light on common key aspects able to improve the typical signs of groin pain. In detail, the rehabilitative programmes should include TA muscle recruitment exercises, core stability exercises, stretching exercises and manual therapy to increase ROM and reduce muscle stiffness. Furthermore, workload must be increased only if the athlete does not feel pain, and the programme must include sport-specific exercises and the return to running programme before the full return to sport.

On the basis of the data included it is quite difficult to define practice guidelines for the management of groin pain in athletes. High quality studies are necessary to define the best rehabilitative treatment algorithm.

This document is protected by international copyright laws. No additional reproduction is authorized. It is permitted for personal use to download and save only one file and print only one copy of this Article. It is not permitted to make additional copies (either sporadically or systematically, either printed or electronic) of the Article for any purpose. It is not permitted to distribute the electronic copy of the article through online internet and/or intranet file sharing systems, electronic mailing or any other means which may allow access to the Article. The use of all or any part of the Article for any Commercial Use is not permitted. The creation of derivative works from the Article is not permitted. The production of reprints for personal or commercial use is not permitted. It is not permitted to remove, cover, overlay, obscure, block, or change any copyright notices or terms of use which the Publisher may post on the Article. It is not permitted to frame or use framing techniques to enclose any trademark, logo, or other proprietary information of the Publisher.

COPYRIGHT© EDIZIONI MINERVA MEDICA

REFERENCES

1. Crockett M, Aherne E, O'Reilly M, Sugrue G, Cashman J, Kavanagh E. Groin Pain in Athletes: A Review of Diagnosis and Management. Surg Technol Int 2015;26: 275-82.

2. LeBlanc KE, LeBlanc KA. Groin pain in athletes. Hernia 2003;7(2): 68-71.

3. Drew MK, Osmotherly PG, Chiarelli PE. Imaging and clinical tests for the diagnosis of long-standing groin pain in athletes. A systematic review. Phys Ther Sport 2014;15(2): 124-9.

4. Ekstrand J, Hilding J. The incidence and differential diagnosis of acute groin injuries in male soccer players. Scandinavian Journal of Medicine & Science in Sports 1999;9(2): 98-103.

5. Harmon KG. Evaluation of groin pain in athletes. Curr Sports Med Rep 2007;6(6): 354-61.

6. Garvey JFW, Hazard H. Sports hernia or groin disruption injury? Chronic athletic groin pain: a retrospective study of 100 patients with long-term follow-up. Hernia 2013;18(6): 815-23.

7. Pogliacomi F, Costantino C, Pedrini MF, Pourjafar S, De Filippo M, Ceccarelli F. Anterior groin pain in athletes as a consequence of bone diseases: etiopathogenesis, diagnosis and principles of treatment. Medicina Dello Sport 2014;67(1): 1-26.

8. Pogliacomi F, Costantino C, Pedrini MF, Pourjafar S, De Filippo M, Ceccarelli F. Anterior groin pain in athletes as a consequence of intra-articular diseases: etiopathogenesis, diagnosis and principles of treatment. Medicina Dello Sport 2014;67(3): 314-68.

9. Dimitrakopoulou A, Schilders E. Sportsman's hernia? An ambiguous term. Journal of Hip Preservation Surgery 2016;3(1): 16-22.

10. Falvey EC, Franklyn-Miller A, McCrory PR. The groin triangle: a patho-anatomical approach to the diagnosis of chronic groin pain in athletes. British Journal of Sports Medicine 2009;43(3): 213-20.

11. Williams P, Foster ME. 'Gilmore's groin'--or is it? Br J Sports Med 1995;29(3): 206-8.

12. Muschaweck U, Berger L. Minimal Repair technique of sportsmen's groin: an innovative open-suture repair to treat chronic inguinal pain. Hernia 2010;14(1): 27-33.

13. Meyers WC, Foley DP, Garrett WE, Lohnes JH, Mandlebaum BR. Management of severe lower abdominal or inguinal pain in high- performance athletes. American Journal of Sports Medicine 2000;28(1): 2-8.

14. Sheen AJ, Iqbal Z. Contemporary management of 'Inguinal disruption' in the sportsman's groin. BMC Sports Sci Med Rehabil 2014;6: 39.

15. Taylor DC, Meyers WC, Moylan JA, Lohnes J, Bassett FH, Garrett WE, Jr. Abdominal musculature abnormalities as a cause of groin pain in athletes. Inguinal hernias and pubalgia. Am J Sports Med 1991;19(3): 239-42.

16. Hegedus EJ, Stern B, Reiman MP, Tarara D, Wright AA. A suggested model for physical examination and conservative treatment of athletic pubalgia. Physical Therapy in Sport 2013;14(1):

This document is protected by international copyright laws. No additional reproduction is authorized. It is permitted for personal use to download and save only one file and print only one copy of this Article. It is not permitted to make additional copies (either sporadically or systematically, either printed or electronic) of the Article for any purpose. It is not permitted to distribute the electronic copy of the article through online internet and/or intranet file sharing systems, electronic mailing or any other means which may allow access to the Article. The use of all or any part of the Article for any Commercial Use is not permitted. The creation of derivative works from the Article is not permitted. The production of reprints for personal or commercial use is not permitted. It is not permitted to remove, cover, overlay, obscure, block, or change any copyright notices or terms of use which the Publisher may post on the Article. It is not permitted to frame or use framing techniques to enclose any trademark, logo, or other proprietary information of the Publisher.

COPYRIGHT© EDIZIONI MINERVA MEDICA

3-16.

17. Oliveira ALD, Andreoli CV, Ejnisman B, Queiroz RD, Pires OGN, Falótico GG. Epidemiological profile of patients diagnosed with athletic pubalgia. Revista Brasileira de Ortopedia 2016;51(6): 692-96.

18. Larruskain J, Lekue JA, Diaz N, Odriozola A, Gil SM. A comparison of injuries in elite male and female football players: A five-season prospective study. Scand J Med Sci Sports 2018;28(1): 237-45.

19. Elattar O, Choi HR, Dills VD, Busconi B. Groin Injuries (Athletic Pubalgia) and Return to Play. Sports Health-a Multidisciplinary Approach 2016;8(4): 313-23.

20. Brophy RH, Backus S, Kraszewski AP, *et al*. Differences Between Sexes in Lower Extremity Alignment and Muscle Activation During Soccer Kick. Journal of Bone and Joint Surgery-American Volume 2010;92A(11): 2050-58.

21. Kluin J, den Hoed PT, van Linschoten R, Ijzerman JC, van Steensel CJ. Endoscopic evaluation and treatment of groin pain in the athlete. American Journal of Sports Medicine 2004;32(4): 944-49.

22. Karlsson MK, Dahan R, Magnusson H, Nyquist F, Rosengren BE. Groin pain and soccer players: male versus female occurrence. Journal of Sports Medicine and Physical Fitness 2014;54(4): 487-93.

23. Larson CM, Lohnes JH. Surgical management of athletic pubalgia. Operative Techniques in Sports Medicine 2002;10(4): 228-32.

24. Hureibi K, McLatchie G. Groin Pain in Athletes. Scottish Medical Journal 2010;55(2): 8-11.

25. Caudill P, Nyland J, Smith C, Yerasimides J, Lach J. Sports hernias: a systematic literature review. Br J Sports Med 2008;42(12): 954-64.

26. Sedaghati P, Alizadeh MH, Shirzad E, Ardjmand A. Review of sport-induced groin injuries. Trauma Mon 2013;18(3): 107-12.

27. Munegato D, Bigoni M, Gridavilla G, Olmi S, Cesana G, Zatti G. Sports hernia and femoroacetabular impingement in athletes: A systematic review. World J Clin Cases 2015;3(9): 823-30.

28. Pogliacomi F, Pedrini MF, Pourjafar S, *et al*. Pubalgia and soccer: real or overestimated problem? Medicina Dello Sport 2015;68(4): 651-62.

29. Bisciotti GN, Auci A, Di Marzo F, *et al*. Groin pain syndrome: an association of different pathologies and a case presentation. Mltj-Muscles Ligaments and Tendons Journal 2015;5(3): 214-22.

30. Paksoy M, Sekmen U. Sportsman hernia; the review of current diagnosis and treatment modalities. Ulus Cerrahi Derg 2016;32(2): 122-9.

31. Garvey JFW, Read JW, Turner A. Sportsman hernia: what can we do? Hernia 2010;14(1): 17-25.

32. Alomar A. Groin pain in athletes: Differential diagnosis, assessment, and management. Saudi

This document is protected by international copyright laws. No additional reproduction is authorized. It is permitted for personal use to download and save only one file and print only one copy of this Article. It is not permitted to make additional copies (either sporadically or systematically, either printed or electronic) of the Article for any purpose. It is not permitted to distribute the electronic copy of the article through online internet and/or intranet file sharing systems, electronic mailing or any other means which may allow access to the Article. The use of all or any part of the Article for any Commercial Use is not permitted. The creation of derivative works from the Article is not permitted. The production of reprints for personal or commercial use is not permitted. It is not permitted to remove, cover, overlay, obscure, block, or change any copyright notices or terms of use which the Publisher may post on the Article. It is not permitted to frame or use framing techniques to enclose any trademark, logo, or other proprietary information of the Publisher.

COPYRIGHT© EDIZIONI MINERVA MEDICA

Journal of Sports Medicine 2015;15(1): 3.

33. Omar IM, Zoga AC, Kavanagh EC, *et al*. Athletic pubalgia and "Sports Hernia": Optimal MR imaging technique and findings. Radiographics 2008;28(5): 1415-38.

34. Edelman DS, Selesnick H. "Sports" hernia: treatment with biologic mesh (Surgisis) - A preliminary study. Surgical Endoscopy and Other Interventional Techniques 2006;20(6): 971-73.

35. Jarosz BS. Individualized multi-modal management of osteitis pubis in an Australian Rules footballer. Journal of Chiropractic Medicine 2011;10(2): 105-10.

36. Campanelli G. Pubic inguinal pain syndrome: the so-called sports hernia. Hernia 2010;14(1): 1-4.

37. Holmich P. Long-standing groin pain in sportspeople falls into three primary patterns, a "clinical entity" approach: a prospective study of 207 patients. British Journal of Sports Medicine 2007;41(4): 247-52.

38. Morales-Conde S, Socas M, Barranco A. Sportsmen hernia: what do we know? Hernia 2010;14(1): 5-15.

39. Sheen AJ, Stephenson BM, Lloyd DM, *et al*. 'Treatment of the Sportsman's groin': British Hernia Society's 2014 position statement based on the Manchester Consensus Conference. British Journal of Sports Medicine 2014;48(14): 1079-87.

40. Weir A, Brukner P, Delahunt E, *et al*. Doha agreement meeting on terminology and definitions in groin pain in athletes. British Journal of Sports Medicine 2015;49(12): 768-774.

41. Kachingwe AF, Grech S. Proposed Algorithm for the Management of Athletes With Athletic Pubalgia (Sports Hernia): A Case Series. Journal of Orthopaedic & Sports Physical Therapy 2008;38(12): 768-81.

42. Falvey ÉC, King E, Kinsella S, Franklyn-Miller A. Athletic groin pain (part 1): A prospective anatomical diagnosis of 382 patients - Clinical findings, MRI findings and patient-reported outcome measures at baseline. British Journal of Sports Medicine 2016;50(7): 423-30.

43. Mens J, Inklaar H, Koes BW, Stam HJ. A new view on adduction-related groin pain. Clinical Journal of Sport Medicine 2006;16(1): 15-19.

44. Khan W, Zoga AC, Meyers WC. Magnetic Resonance Imaging of Athletic Pubalgia and the Sports Hernia Current Understanding and Practice. Magnetic Resonance Imaging Clinics of North America 2013;21(1): 97-110.

45. Serner A, Jakobsen MD, Andersen LL, Hölmich P, Sundstrup E, Thorborg K. EMG evaluation of hip adduction exercises for soccer players: Implications for exercise selection in prevention and treatment of groin injuries. British Journal of Sports Medicine 2014;48(14): 1108-14.

46. Mohammad WS, Abdelraouf OR, Elhafez SM, Abdel-Aziem AA, Nassif NS. Isokinetic imbalance of hip muscles in soccer players with osteitis pubis. Journal of Sports Sciences

This document is protected by international copyright laws. No additional reproduction is authorized. It is permitted for personal use to download and save only one file and print only one copy of this Article. It is not permitted to make additional copies (either sporadically or systematically, either printed or electronic) of the Article for any purpose. It is not permitted to distribute the electronic copy of the article through online internet and/or intranet file sharing systems, electronic mailing or any other means which may allow access to the Article. The use of all or any part of the Article for any Commercial Use is not permitted. The creation of derivative works from the Article is not permitted. The production of reprints for personal or commercial use is not permitted. It is not permitted to remove, cover, overlay, obscure, block, or change any copyright notices or terms of use which the Publisher may post on the Article. It is not permitted to frame or use framing techniques to enclose any trademark, logo, or other proprietary information of the Publisher.

COPYRIGHT© EDIZIONI MINERVA MEDICA

2014;32(10): 934-39.

47. Farber AJ, Wilckens JH. Sports hernia: Diagnosis and therapeutic approach. Journal of the American Academy of Orthopaedic Surgeons 2007;15(8): 507-14.

48. Jans C, Messaoudi N, Pauli S, Van Riet RP, Declercq G. Results of surgical treatment of athletes with sportsman's hernia. Acta Orthopaedica Belgica 2012;78(1): 35-40.

49. McSweeney SE, Naraghi A, Salonen D, Theodoropoulos J, White LM. Hip and Groin Pain in the Professional Athlete. Canadian Association of Radiologists Journal-Journal De L Association Canadienne Des Radiologistes 2012;63(2): 87-99.

50. Hammoud S, Bedi A, Magennis E, Meyers WC, Kelly BT. High Incidence of Athletic Pubalgia Symptoms in Professional Athletes With Symptomatic Femoroacetabular Impingement. Arthroscopy-the Journal of Arthroscopic and Related Surgery 2012;28(10): 1388-95.

51. Serner A, van Eijck CH, Beumer BR, Holmich P, Weir A, de Vos RJ. Study quality on groin injury management remains low: a systematic review on treatment of groin pain in athletes. Br J Sports Med 2015;49(12): 813.

52. OCEBM Levels of Evidence Working Group. The Oxford 2011 Levels of Evidence. Oxford Centre for Evidence Based Medicine.

53. Holmich P, Nyvold P, Larsen K. Continued Significant Effect of Physical Training as Treatment for Overuse Injury 8-to 12-Year Outcome of a Randomized Clinical Trial. American Journal of Sports Medicine 2011;39(11): 2447-51.

54. Holmich P, Uhrskou P, Ulnits L, *et al*. Effectiveness of active physical training as treatment for long-standing adductor-related groin pain in athletes: randomised trial. Lancet 1999;353(9151): 439-43.

55. Weir A, Jansen JACG, van de Port IGL, Van de Sande HBA, Tol JL, Backx FJG. Manual or exercise therapy for long-standing adductor-related groin pain: A randomised controlled clinical trial. Manual Therapy 2011;16(2): 148-54.

56. Jansen J, Mens JMA, Backx FJG, Stam HJ. Changes in Abdominal Muscle Thickness Measured by Ultrasound Are Not Associated With Recovery in Athletes With Longstanding Groin Pain Associated With Resisted Hip Adduction. Journal of Orthopaedic & Sports Physical Therapy 2009;39(10): 724-32.

57. Verrall GM, Slavotinek JP, Fon GT, Barnes PG. Outcome of conservative management of athletic chronic groin injury diagnosed as pubic bone stress injury. American Journal of Sports Medicine 2007;35(3): 467-74.

58. Weir A, Jansen J, van Keulen J, Mens J, Backx F, Stam H. Short and mid-term results of a comprehensive treatment program for longstanding adductor-related groin pain in athletes: A case series. Physical Therapy in Sport 2010;11(3): 99-103.

This document is protected by international copyright laws. No additional reproduction is authorized. It is permitted for personal use to download and save only one file and print only one copy of this Article. It is not permitted to make additional copies (either sporadically or systematically, either printed or electronic) of the Article for any purpose. It is not permitted to distribute the electronic copy of the article through online internet and/or intranet file sharing systems, electronic mailing or any other means which may allow access to the Article. The use of all or any part of the Article for any Commercial Use is not permitted. The creation of derivative works from the Article is not permitted. The production of reprints for personal or commercial use is not permitted. It is not permitted to remove, cover, overlay, obscure, block, or change any copyright notices or terms of use which the Publisher may post on the Article. It is not permitted to frame or use framing techniques to enclose any trademark, logo, or other proprietary information of the Publisher.

COPYRIGHT© EDIZIONI MINERVA MEDICA

59. Weir A, Veger SAS, Van de Sande HBA, Bakker EWP, de Jonge S, Tol JL. A manual therapy technique for chronic adductor-related groin pain in athletes: a case series. Scandinavian Journal of Medicine & Science in Sports 2009;19(5): 616-20.

60. Wollin M, Lovell G. Osteitis pubis in four young football players: A case series demonstrating successful rehabilitation. Physical Therapy in Sport 2006;7(3): 153-60.

61. Navot S, Kalichman L. Hip and groin pain in a cyclist resolved after performing a pelvic floor fascial mobilization. Journal of Bodywork and Movement Therapies 2016;20(3): 604-09.

62. Sudarshan A. Physical therapy management of osteitis pubis in a 10-year-old cricket fast bowler. Physiotherapy Theory and Practice 2013;29(6): 476-86.

63. Reiman MP, Manske RC. The assessment of function. Part II: Clinical perspective of a javelin thrower with low back and groin pain. Journal of Manual and Manipulative Therapy 2012;20(2): 83-89.

64. Esteve E, Rathleff MS, Bagur-Calafat C, Urrutia G, Thorborg K. Prevention of groin injuries in sports: a systematic review with meta-analysis of randomised controlled trials. Br J Sports Med 2015;49(12): 785-91.

This document is protected by international copyright laws. No additional reproduction is authorized. It is permitted for personal use to download and save only one file and print only one copy of this Article. It is not permitted to make additional copies (either sporadically or systematically, either printed or electronic) of the Article for any purpose. It is not permitted to distribute the electronic copy of the article through online internet and/or intranet file sharing systems, electronic mailing or any other means which may allow access to the Article. The use of all or any part of the Article for any Commercial Use is not permitted. The creation of derivative works from the Article is not permitted. The production of reprints for personal or commercial use is not permitted. It is not permitted to remove, cover, overlay, obscure, block, or change any copyright notices or terms of use which the Publisher may post on the Article. It is not permitted to frame or use framing techniques to enclose any trademark, logo, or other proprietary information of the Publisher.

COPYRIGHT© EDIZIONI MINERVA MEDICA

FIGURE AND TABLES LEGEND

Figure 1. Most frequent pathologies which cause anterior pelvic/groin pain (modified from Pogliacomi et al., 2014[7]).

Figure 2. Study selection process. Electronic databases searched were PubMed, Physiotherapy Evidence Database (PEDro), Scopus and Web of Science. Other sources were Google and Google Scholar.

Table I. Inguinal disruption clinical signs (modified from Dimitrakopoulou & Schilders, 2016[9]).

Table II. Study design quality assessment based on PEDro scale score.

Table III. Population and clinical examination of athletes.

Table IV. Details of treatment strategies for groin pain in athletes.

FUNDING

No sources of funding were used to assist in the preparation of this article.

CONFLICTS OF INTEREST

The authors certify that there is no conflict of interest with any financial organization regarding the material discussed in the manuscript.

This document is protected by international copyright laws. No additional reproduction is authorized. It is permitted for personal use to download and save only one file and print only one copy of this Article. It is not permitted to make additional copies (either sporadically or systematically, either printed or electronic) of the Article for any purpose. It is not permitted to distribute the electronic copy of the article through online internet and/or intranet file sharing systems, electronic mailing or any other means which may allow access to the Article. The use of all or any part of the Article for any Commercial Use is not permitted. The creation of derivative works from the Article is not permitted. The production of reprints for personal or commercial use is not permitted. It is not permitted to remove, cover, overlay, obscure, block, or change any copyright notices or terms of use which the Publisher may post on the Article. It is not permitted to frame or use framing techniques to enclose any trademark, logo, or other proprietary information of the Publisher.

COPYRIGHT© EDIZIONI MINERVA MEDICA

Table I. Inguinal disruption clinical signs (modified from Dimitrakopoulou & Schilders, 2016[9]).

Clinical signs
1. Dull, diffuse pain in the groin, often radiating to the perineum and inner thigh or across the midline.
2. Pinpoint tenderness over the pubic tubercle at the point of insertion of the conjoint tendon.
3. Palpable tenderness over the deep inguinal ring.
4. Pain and/or dilation of the external ring with no obvious hernia evident.
5. Pain at the origin of the adductor longus tendon.

This document is protected by international copyright laws. No additional reproduction is authorized. It is permitted for personal use to download and save only one file and print only one copy of this Article. It is not permitted to make additional copies (either sporadically or systematically, either printed or electronic) of the Article for any purpose. It is not permitted to distribute the electronic copy of the article through online internet and/or intranet file sharing systems, electronic mailing or any other means which may allow access to the Article. The use of all or any part of the Article for any Commercial Use is not permitted. The creation of derivative works from the Article is not permitted. The production of reprints for personal or commercial use is not permitted. It is not permitted to remove, cover, overlay, obscure, block, or change any copyright notices or terms of use which the Publisher may post on the Article. It is not permitted to frame or use framing techniques to enclose any trademark, logo, or other proprietary information of the Publisher.

COPYRIGHT© EDIZIONI MINERVA MEDICA

Table II. Study design quality assessment based on PEDro scale score.

Study	1	2	3	4	5	6	7	8	9	10	11	Total score
Holmich et al., 1999[54]	X	X	X	X			X	X	X	X	X	**8**
Holmich et al., 2011[53]		X		X			X			X	X	**5**
Weir et al., 2011[55]	X	X	X	X			X	X		X	X	**7**

PEDro criteria: 1-Eligibility criteria (not used to calculate the PEDro score); 2-Random allocation; 3-Concealed allocation; 4-Baseline comparability; 5-Blind subjects; 6-Blind therapists; 7-Blind assessors; 8-Adequate follow-up; 9-Intention-to-treat analysis; 10-Between-group comparisons; 11-Point estimates and variability provided.

This document is protected by international copyright laws. No additional reproduction is authorized. It is permitted for personal use to download and save only one file and print only one copy of this Article. It is not permitted to make additional copies (either sporadically or systematically, either printed or electronic) of the Article for any purpose. It is not permitted to distribute the electronic copy of the article through online internet and/or intranet file sharing systems, electronic mailing or any other means which may allow access to the Article. The use of all or any part of the Article for any Commercial Use is not permitted. The creation of derivative works from the Article is not permitted. The production of reprints for personal or commercial use is not permitted. It is not permitted to remove, cover, overlay, obscure, block, or change any copyright notices or terms of use which the Publisher may post on the Article. It is not permitted to frame or use framing techniques to enclose any trademark, logo, or other proprietary information of the Publisher.

COPYRIGHT© EDIZIONI MINERVA MEDICA

Table III. Population and clinical examination of athletes.

Study	Sport	Study population	Clinical examination
Holmich et al., 1999[54] (RCT)	Soccer-Running-Rugby-Tennis-Handball-Badminton-Basketball-Ice hockey-Horse riding	68 male athletes (18-50 y) AT group: 34 (5 wd) PT group: 34 (4 wd) Groin pain for at least 2 months	Clinical examination protocol-Questionnaire-Plain pelvis radiograph-Bone scintigraphy
Holmich et al., 2011[53] (RCT)	Soccer-Running-Handball- Rugby-Badminton-Ice hockey	59 male athletes AT group: 29 (5 wd) PT group: 30 (7 wd)	Clinical examination protocol-Questionnaire
Weir et al., 2011[55] (RCT)	Soccer-Rugby-Squash-Running-Field hockey-Speed skating-Other sports	54 athletes (18-50 y) ET group: 25 (3 wd) MMT group: 29 (3 wd) Groin pain for at least 2 months	Clinical examination protocol-ROM measurement-VAS
Jansen et al., 2009[56] (single-cohort study)	Fitness-Running-Soccer-Speed skating-Rugby	21 athletes (18-45 y) Groin pain for at least 4 weeks	Questionnaire-US imaging-11 point Likert scale-ASLR test-Squeeze test
Verrall et al., 2007[57] (case series)	Football	27 male athletes (18-29 y) Groin pain for at least 6 weeks	Questionnaire-Squeeze test-Point tenderness examination-Bilateral adductor test-MRI-Hip provocation test
Weir et al., 2009[59] (case series)	Soccer-Tennis-Running-Speed skating	30 athletes (median age 20.5 y) Groin pain for at least 2 months	Pain on palpation-Resisted adduction test
Weir et al., 2010[58] (case series)	Soccer-Running-Tennis-Field hockey-Other sports	44 athletes (27 ± 10.8 y) Groin pain for at least 4 weeks	Pain on palpation-Resisted adduction test
Wollin & Lovell, 2006[60] (case series)	Football	Male, 17 y, groin pain 2 weeks after sport Male, 16 y, groin pain after training intensity increase Male, 16 y, groin pain following many highly competitive games Male, 17 y, groin pain during activity	Squeeze test-Pubic symphysis palpation-PSST-MRI
Navot & Kalichman, 2016[61] (case report)	Cycling	32 y male athlete with groin pain after a severe hip contusion and tear of fascia lata and gluteus medius muscles	ROM measurement-Pelvic floor muscle active contractions-Palpation
Sudarshan, 2013[62] (case report)	Cricket	10 y male athlete with groin pain for two and half months	LEFS-VAS-ROM measurement-Valsalva manoeuvre-Gillet test-Postural/Gait analysis-Sitting/Standing flexion test-Thomas/Long set test-Prone knee bend test-Neuromuscular tests-Sacroiliac pain test cluster-FADIR impingement test
Reiman & Manske, 2012[63] (case report)	Javelin	26 y male athlete with groin pain for at least 2 weeks	Bilateral and single leg squat-PPMs-SRMs-FADIR impingement test-Sacroiliac joint thrust test

RCT: Randomized Control Trial; AT: Active Training; PT: Physiotherapy Treatment without active training; y: years; ASLR: Active Straight-Leg Raise; US: Ultrasound; MRI: Magnetic Resonance Imaging; ET: Exercise Therapy; MMT: Multi-Modal Treatment Programme; ROM: Range of Motion; VAS: Visual Analogue Scale; LEFS: Lower Extremity Functional Scale; PSST: Pubic Symphysis Stress Test; FADIR: Flexion-Adduction-Internal Rotation; PPMs: Physical Performance Measurements; SRMs: Self-Reported measures.

This document is protected by international copyright laws. No additional reproduction is authorized. It is permitted for personal use to download and save only one file and print only one copy of this Article. It is not permitted to make additional copies (either sporadically or systematically, either printed or electronic) of the Article for any purpose. It is not permitted to distribute the electronic copy of the article through online internet and/or intranet file sharing systems, electronic mailing or any other means which may allow access to the Article. The use of all or any part of the Article for any Commercial Use is not permitted. The creation of derivative works from the Article is not permitted. The production of reprints for personal or commercial use is not permitted. It is not permitted to remove, cover, overlay, obscure, block, or change any copyright notices or terms of use which the Publisher may post on the Article. It is not permitted to frame or use framing techniques to enclose any trademark, logo, or other proprietary information of the Publisher.

COPYRIGHT© EDIZIONI MINERVA MEDICA

Table IV. Details of treatment strategies for groin pain in athletes.

Study	Treatments	Outcomes
Holmich et al., 1999[53,54] (RCT)	AT group: 3 times a week for 8-12 weeks. First 2 weeks: static adduction; abdominal sit-ups; abdominal sit-up and hip flexion; balance training; one-foot exercises. From third week: leg adduction; low-back extension; one-leg weight-pulling abduction; abdominal sit-ups; balance training; skating movements. PT group: twice a week for 8-12 weeks. Laser treatment; transcutaneous electrical nerve stimulation; transverse friction massage; adductor, hamstring and hip flexor stretching.	AT treatment group: 23 (79%) returned to sports activity at their previous level or higher (median time: 18.5 weeks) without groin pain. PT group: only 4 (14%) patients returned to sports activity without groin pain. The adduction strength improved significantly in the AT group with respect to the PT group whereas no differences in ROM hip abduction was highlighted between the groups. Data showed a significant difference in favour of the AT strategy. The 8- to 12-year follow-up study highlighted that the beneficial effect of the AT reported in the primary RCT51 was lasting.
Weir et al., 2011[55] (RCT)	ET group: 3 times a week. Holmich et al. protocol[54] and "return to running" programme (slow jogging; straight sprints; sprints with changing directions). MMT group: muscle heat, manual therapy, adductor stretching; running programme after 14 days of stretching.	Athletes in MMT group returned to sports quicker than athletes in ET group (12.8 ± 6.0 and 17.3 ± 4.4 weeks, respectively). The percentage of athletes who returned to sport activity was not different between the groups (50-55%). There was no significant difference in objective outcome or VAS between the groups.
Jansen et al., 2009[56] (single-cohort study)	14 weeks of treatment from twice to once a week. 1st phase: TA recruitment; passive joint mobilization or manipulation techniques; abdominal muscles respiratory activity. 2nd phase: abdominal and back muscles recruitment. 3rd phase: prone, lateral and back bridge. 4th phase: Holmich et al. programme[54] and home exercises.	Sports participation restriction and pain during the squeeze test were significantly decreased following intervention. TA resting thickness, measured by US imaging, was significantly increased after intervention. Data showed no significant association between abdominal muscle thickness and change in athletes' sports restriction.
Verrall et al., 2007[57] (case series)	Athletes were followed for 2 playing seasons. 1st phase: 12 weeks rest or activities with no pain. 2nd phase: activity on stepping device 5 min/days, increasing 1 min/day if the athletes were pain free. 3rd phase: 5 min running session, increasing 1 min/session until 30 min of running (interval running 500 m). If 30 min pain-free interval running is tolerated athletes will return to football training. Pelvic/core stability exercises from 3-6 weeks.	89% athletes returned to competition in the first football season, and 100% by the second one. 41% of athletes were without symptoms at the beginning of the first football season; 81% by the end of the second one. 26% of athletes were playing at a lower competition level in the second season.
Weir et al., 2009[59] (case series)	Manual therapy; 5 min warm-up, adductor stretching, 10 min warm bath. After 14 days athletes start training activities and then progress to competitive sports. Protocol treatment was repeated maximum twice.	25/30 athletes were treated once and 5/30 twice. 15 athletes returned at pre-injury level, 12 returned under pre-injury level and 3 did not return to sports. The pain score decreased statistically.

This document is protected by international copyright laws. No additional reproduction is authorized. It is permitted for personal use to download and save only one file and print only one copy of this Article. It is not permitted to make additional copies (either sporadically or systematically, either printed or electronic) of the Article for any purpose. It is not permitted to distribute the electronic copy of the article through online internet and/or intranet file sharing systems, electronic mailing or any other means which may allow access to the Article. The use of all or any part of the Article for any Commercial Use is not permitted. The creation of derivative works from the Article is not permitted. The production of reprints for personal or commercial use is not permitted. It is not permitted to remove, cover, overlay, obscure, block, or change any copyright notices or terms of use which the Publisher may post on the Article. It is not permitted to frame or use framing techniques to enclose any trademark, logo, or other proprietary information of the Publisher.

COPYRIGHT© EDIZIONI MINERVA MEDICA

Weir et al., 2010[58] (case series)	Refrain from competitive activity for a minimum of 3 weeks. 1st phase: hip, sacroiliac, lumbar spine mobilization; basic TA recruitment. 2nd phase: TA recruitment; core stability; hip adduction. 3rd phase: whole body stabilizing exercises; progressive hip adduction strength exercise; running. 4-5th phase: agility drills; sport-exercises; return to sports. Phase 1-4: physiotherapy session once a week; exercises twice a week without supervision (90 min/session).	After treatment 38 athletes returned to their same sport level (34 without any symptoms). Median of return to sport activity was 142 days. At mid-term follow up (median 22 months) 23/44 athletes were active at their previous level of sports and 5 were active at a higher level; 10/38 athletes had experienced a groin pain recurrence.
Wollin & Lovell, 2006[60] (case series)	Module 1: pelvic floor and TA retraining; isometric hip adduction. Module 2-4: progressive core stability; gluteal and adductor conditioning; running programmes.	All players returned to football 10-16 weeks after treatment. No injury recurrence event has been reported. Athletes returned to their pre-injury fitness level.
Navot & Kalichman, 2016[61] (case report)	Two treatment session, 7 days apart: internal pelvic floor fascial mobilization; hip stabilizing exercises (one-legged squats, step-up/step-down, lunges as conventional recommended exercise for hip).	Significant hip joint ROM and pelvic floor muscles improvement after the first treatment. Pain decreased statistically after treatment. Athlete returned to his usual sports and work activity.
Sudarshan, 2012[62] (case report)	One session/week for 9 weeks. 1st phase: stretching; hip mobilization; sacroiliac manipulation; TA/gluteal isometric contraction; hip extension; pelvic bridging; core stability; home exercises. 2nd phase: progressive core exercises; TA contraction; wall sliding/pelvic drop/quadruped position exercises; walk 20 min. 3rd phase: cricket agility exercises and swimming.	VAS score reduced from 7.2 to 0.8. LEFS score increased from 21 to 73. At 6 month follow-up patient was completely pain free.
Reiman & Manske, 2012[63] (case report)	Orthopaedic manual therapy; gluteal and trunk stabilization exercises; self-mobilization of posterior hip; aquatic training and upper body ergometer; strength exercises; running, jumping drills and sports-specific training integrated with rehabilitation.	After six treatment sessions athlete was able to return to a progressive, periodized sport training programme. At 6 month follow-up patient performed normal training and job duties.

RCT: Randomized Clinical Trial; AT: Active Training; PT: Physiotherapy Treatment without active training; TA: Transversus Abdominis muscle; US: Ultrasound; ET: Exercise Therapy; MMT: Multi-Modal Treatment; VAS: Visual Analogue Scale; ADL: Activities of Daily Living; ROM: Range Of Motion; LEFS: Lower Extremity Functional Scale.

This document is protected by international copyright laws. No additional reproduction is authorized. It is permitted for personal use to download and save only one file and print only one copy of this Article. It is not permitted to make additional copies (either sporadically or systematically, either printed or electronic) of the Article for any purpose. It is not permitted to distribute the electronic copy of the article through online internet and/or intranet file sharing systems, electronic mailing or any other means which may allow access to the Article. The use of all or any part of the Article for any Commercial Use is not permitted. The creation of derivative works from the Article is not permitted. The production of reprints for personal or commercial use is not permitted. It is not permitted to remove, cover, overlay, obscure, block, or change any copyright notices or terms of use which the Publisher may post on the Article. It is not permitted to frame or use framing techniques to enclose any trademark, logo, or other proprietary information of the Publisher.

COPYRIGHT© EDIZIONI MINERVA MEDICA

APPENDIX A: DETAILED ELECTRONIC DATABASE SEARCH STRATEGIES

Web of Science strategy

((pubalgia OR pubialgia OR osteitis pubis OR groin pain OR Chronic groin pain OR groin injury OR sport hernia OR sports-related groin pain OR sportsman's hernia OR adductor tendin* OR adductor tendon*OR pubic inguinal pain syndrome OR inguinal disruption OR core muscle injury OR hockey player's syndrome OR footballers groin injury complex OR gilmore's groin OR Symphisis Syndrome OR iliopsoas dysfunction OR pubic bone stress Or posterior inguinal wall) AND (athlet* or sport*): LANGUAGES: (ENGLISH) AND [excluding]: WEB OF SCIENCE CATEGORIES: (VETERINARY SCIENCES) sport*))

(((pubalgia OR pubialgia OR osteitis pubis OR groin pain OR Chronic groin pain OR groin injury OR sport hernia OR sports- related groin pain OR sportsman's hernia OR adductor tendin* OR adductor tendon*OR pubic inguinal pain syndrome OR inguinal disruption OR core muscle injury OR hockey player's syndrome OR footballers groin injury complex OR gilmore's groin OR Symphisis Syndrome OR iliopsoas dysfunction OR pubic bone stress Or posterior inguinal wall) AND (athlet* or sport*) AND (rehabilitation or intervention)))
LANGUAGES: (ENGLISH)

PubMed strategy

pubalgia[tiab] OR pubialgia[tiab] OR osteitis pubis[tiab] OR groin pain[tiab] OR Chronic groin pain[tiab] OR groin injury[tiab] OR sport hernia[tiab] OR sports- related groin pain[tiab] OR sportsman's hernia[tiab] OR adductor tendin*[tiab] OR adductor tendon*[tiab] OR femoroacetabular impingement[tiab] OR pubic inguinal pain syndrome[tiab] OR inguinal disruption[tiab] OR core muscle injury[tiab] OR hockey player's syndrome[tiab] OR footballers groin injury complex[tiab] OR gilmore's groin[tiab] OR Symphisis Syndrome[tiab] OR iliopsoas dysfunction[tiab] OR pubic bone stress[tiab] Or posterior inguinal wall[tiab]) AND (athlet*[tiab] or sport*[tiab])
Filters:

- ✓ humans
- ✓ English
- ✓ last 10 years

pubalgia[tiab] OR pubialgia[tiab] OR osteitis pubis[tiab] OR groin pain[tiab] OR Chronic groin pain[tiab] OR groin injury[tiab] OR sport hernia[tiab] OR sports- related groin pain[tiab] OR sportsman's hernia[tiab] OR adductor tendin*[tiab] OR adductor tendon*[tiab] OR pubic inguinal pain sy layer's

This document is protected by international copyright laws. No additional reproduction is authorized. It is permitted for personal use to download and save only one file and print only one copy of this Article. It is not permitted to make additional copies (either sporadically or systematically, either printed or electronic) of the Article for any purpose. It is not permitted to distribute the electronic copy of the article through online internet and/or intranet file sharing systems, electronic mailing or any other means which may allow access to the Article. The use of all or any part of the Article for any Commercial Use is not permitted. The creation of derivative works from the Article is not permitted. The production of reprints for personal or commercial use is not permitted. It is not permitted to remove, cover, overlay, obscure, block, or change any copyright notices or terms of use which the Publisher may post on the Article. It is not permitted to frame or use framing techniques to enclose any trademark, logo, or other proprietary information of the Publisher.

COPYRIGHT© EDIZIONI MINERVA MEDICA

syndrome[tiab] OR footballers groin injury complex[tiab] OR gilmore's groin[tiab] OR Symphisis Syndrome[tiab] OR iliopsoas dysfunction[tiab] OR pubic bone stress[tiab] Or posterior inguinal wall[tiab]) AND (athlet*[tiab] or sport*[tiab]) And (rehabilitation[tiab] or intervention[tiab])

Filters:

- ✓ humans
- ✓ English
- ✓ last 10 years
- ✓ no femoroacetabular impingement

Scopus strategy

((pubalgia OR pubialgia OR osteitis AND pubis OR groin AND pain OR Chronic AND groin AND pain OR groin AND injury OR sport AND hernia OR sports- related AND groin AND pain OR sportsman's AND hernia OR adductor AND tendin* OR adductor AND tendon* OR pubic AND inguinal AND pain AND syndrome OR inguinal AND disruption OR core AND muscle AND injury OR hockey AND player's AND syndrome OR footballers AND groin AND injury AND complex OR gilmore's AND groin OR Symphisis AND Syndrome OR iliopsoas AND dysfunction OR pubic AND bone stress Or posterior AND inguinal AND wall) AND (athlet*or sport*) AND (LIMIT-TO (LANGUAGE ,"English"))

PEDro strategy

Pubalgia and sport; Groin pain and sport; Osteitis pubis and sport; Chronic groin pain and sport; Groin injury and sport; Sport hernia and sport; Sports-related groin pain and sport; Sportsman’s hernia and sport; Adductor tendin and sport; Adductor tendon and sport; Pubic inguinal pain syndrome and sport; Inguinal disruption and sport; Core muscle injury and sport; Hockey player's syndrome and sport; Footballers groin injury complex and sport; Gilmore's groin and sport; Symphisis syndrome and sport; Iliopsoas dysfunction and sport; Pubic bone stress and sport; Posterior inguinal wall and sport.

This document is protected by international copyright laws. No additional reproduction is authorized. It is permitted for personal use to download and save only one file and print only one copy of this Article. It is not permitted to make additional copies (either sporadically or systematically, either printed or electronic) of the Article for any purpose. It is not permitted to distribute the electronic copy of the article through online internet and/or intranet file sharing systems, electronic mailing or any other means which may allow access to the Article. The use of all or any part of the Article for any Commercial Use is not permitted. The creation of derivative works from the Article is not permitted. The production of reprints for personal or commercial use is not permitted. It is not permitted to remove, cover, overlay, obscure, block, or change any copyright notices or terms of use which the Publisher may post on the Article. It is not permitted to frame or use framing techniques to enclose any trademark, logo, or other proprietary information of the Publisher.

COPYRIGHT© EDIZIONI MINERVA MEDICA

Figure 1. Most frequent pathologies which cause anterior pelvic/groin pain (modified from Pogliacomi et al., 2014[7]).

This document is protected by international copyright laws. No additional reproduction is authorized. It is permitted for personal use to download and save only one file and print only one copy of this Article. It is not permitted to make additional copies (either sporadically or systematically, either printed or electronic) of the Article for any purpose. It is not permitted to distribute the electronic copy of the article through online internet and/or intranet file sharing systems, electronic mailing or any other means which may allow access to the Article. The use of all or any part of the Article for any Commercial Use is not permitted. The creation of derivative works from the Article is not permitted. The production of reprints for personal or commercial use is not permitted. It is not permitted to remove, cover, overlay, obscure, block, or change any copyright notices or terms of use which the Publisher may post on the Article. It is not permitted to frame or use framing techniques to enclose any trademark, logo, or other proprietary information of the Publisher.

COPYRIGHT© EDIZIONI MINERVA MEDICA

Figure 2. Study selection process. Electronic databases searched were PubMed, Physiotherapy Evidence Database (PEDro), Scopus and Web of Science. Other sources were Google and Google Scholar.

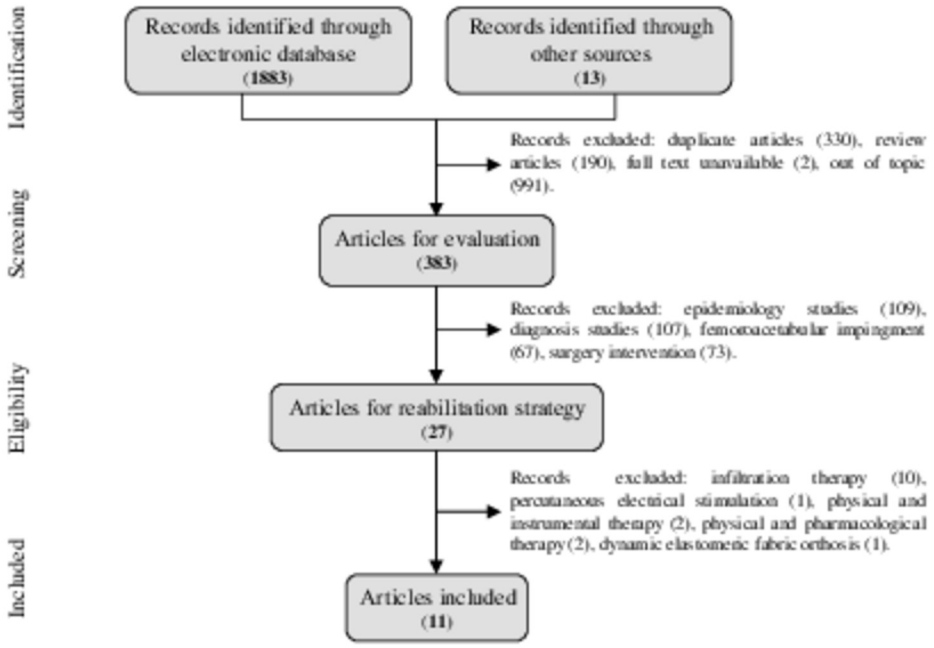

This document is protected by international copyright laws. No additional reproduction is authorized. It is permitted for personal use to download and save only one file and print only one copy of this Article. It is not permitted to make additional copies (either sporadically or systematically, either printed or electronic) of the Article for any purpose. It is not permitted to distribute the electronic copy of the article through online internet and/or intranet file sharing systems, electronic mailing or any other means which may allow access to the Article. The use of all or any part of the Article for any Commercial Use is not permitted. The creation of derivative works from the Article is not permitted. The production of reprints for personal or commercial use is not permitted. It is not permitted to remove, cover, overlay, obscure, block, or change any copyright notices or terms of use which the Publisher may post on the Article. It is not permitted to frame or use framing techniques to enclose any trademark, logo, or other proprietary information of the Publisher.